

Case Report

Emergence of a Tape-worm Through Traumatic Perforation of the Small Intestine, Then Through the Umbilical Wound to the Exterior, Elhassaheisa Teaching Hospital, Sudan

Omer Taha Ahmed Elmukashfi^{1,*}, Taha Ahmed Elmukashfi Elshiekh²,
Mohammed Algily Dafalla Mohammed¹, Imtethal Ali Mahmoud Abdruhman³

¹General Surgery Council, Sudan Medical Specialization Board, Khartoum, Sudan

²Department of Community Medicine, Faculty of Medicine, University of Khartoum, Khartoum, Sudan

³Department of Training, Federal Ministry of Health, Khartoum, Sudan

Email address:

omertaha94@gmail.com (O. T. A. Elmukashfi)

*Corresponding author

To cite this article:

Omer Taha Ahmed Elmukashfi, Taha Ahmed Elmukashfi Elshiekh, Mohammed Algily Dafalla Mohammed, Imtethal Ali Mahmoud Abdruhman. Emergence of a Tape-worm Through Traumatic Perforation of the Small Intestine, Then Through the Umbilical Wound to the Exterior, Elhassaheisa Teaching Hospital, Sudan. *Central African Journal of Public Health*. Vol. 6, No. 5, 2020, pp. 316-319. doi: 10.11648/j.cajph.20200605.21

Received: July 23, 2020; Accepted: October 5, 2020; Published: October 17, 2020

Abstract: Tapeworm infection represents a common health problem in developing countries. *Taeniasaginata* infection is one of endemic diseases that found in countries where most of populations eat raw or undercooked meat. A 64 years old female patient with penetrating abdominal trauma, presented to Outpatient Clinic at Elhassaheisa Teaching Hospital, Gezira State, Sudan; December 2019. On examination patient looks unwell, not pale, vitally stable, fully conscious, abdomen moving with respiration with an open wound at umbilical region, and there is a tape worm moving outside abdomen through site of trauma. Patient immediately received intravenous fluids and antibiotics together with anti tetanus. An emergency laparotomy was performed with suspicion of perforated viscous. It was found that ileum was herniated through lineasemilunaris with three sites of perforation about 60cm from ileocecal valve. The affected part was resected and anastomosed, approximation of defect of lineasemilunaris was performed, pelvic drain was fixed, hemostasis was secure, and no other tape-worm was found. Patient had a positive history of eating raw meats, loss of appetite, cholecystitis and frequent epigastric pain. Test for *TaeniaSaginata* was positive for patient and negative for her family. Patient was discharged on seventh day of operation in a good condition and on Albendazole tab. Seven days later after discharge she came for follow up and she was quite well. In this case, size of intestinal perforation was of adequate size through which tape-worm can emerge out of intestine. So, most probably worm emerged through perforation of intestine then through umbilical wound to exterior.

Keywords: *TaeniaSaginata*, Penetrating Abdominal Wound, Sudan

1. Introduction

Tapeworm infection is one of the most common health problems. Man is a definitive host for two species: *TaeniaSolium* receives from pig as intermediate host and *TaeniaSaginata* receive from cattle as intermediate host. This tapeworm reproduces by production of proglottids in intestine which detaches and passes within stool. So, it can be ingested

by animal, then release oncosphere in intestine and move to muscles forming cysticercus, which can survive for many years, and can be consumed by man after eating undercooked meat. Eggs can transform into adult tapeworm over 2 months and last for more than 30 years. Tape worm are large worms which can infest gastrointestinal tract by ingestion of viable larva of worm in undercooked muscle of beef or pork. *Taeniasaginata* infection is one of endemic diseases that found

in countries where most of populations eat raw or undercooked meat; it's reported in India as 9.7% to 18.6%. *TaeniaSaginata* is predominant in Muslims countries as pork is rarely consumed. It represents a common health problem in developing countries including India, Indonesia, Africa, Peru, and Mexico. [1-7]. *Taeniaspp* infection is endemic in Latin America, Southeast Asia, and Africa, it can lead to taeniasis which is the intestinal manifestation of taenai in which the patient can revealed no symptoms or can experience a passage of tape worm segment, abdominal cramps, weight loss, loss of appetite, and insomnia [8]. *TaeniaSaginata* can result in many complications as intestinal obstruction, perforation, appendicular stump dehiscence and faecal fistula in post appendectomy patient [9]. One of the causes that result in abnormal vaginal bleeding is tapeworm infestation which can mimics retained products of conception in an old multipara [3]. One of the forms of tapeworm infestation is ocular cysticercosis that is endemic in tropical area like India, which cause by *TaeniaSolium* involving any part of the eye. It accounts for 1.4%-4.5% of cases of cysticercosis. The rate of involvement of the posterior segment of the eye is 68%, anterior segment is 8%, and eyelid or orbit is 4%. Isolated sub-conjunctival cysticercus cyst can easily be misdiagnosed as nodular episcleritis [10]. Cysticercosis is one of the most common health issues in developed and under-developed countries and it's the single most common cause of epilepsy that result in neurocysticercosis in which the *TaeniaSolium* involved the nervous system especially in the under-developed countries like: South and Central America, India, South -east China and Sub-Saharan Africa [6]. One of the common infestation of *TaeniaSolium* that caused by its larva is cysticercosis which involve the nervous system. The involvement of the orbit and the adenexa represent 13% to 46% of all systemic diseases. In India the most common site involved is the orbit and adnexa while in Western World is the vitreous cavity or the sub-retinal space. Extra ocular muscle is commonly involved in orbital cysticercosis. The incidence of sub-conjunctivalcysticercous cyst among the cystic lesions of conjunctiva is 8.89% [11]. *TaeniaSolium* is the tapeworm that can cause tiniasis as it infects the intestine and can result in cysticercosis as it infects the tissue. Patient can be asymptomatic or can present with anemia, loss of appetite and emaciation, and abdominal wall swelling. Cysticercosis can be asymptomatic for years or it can present with one or two painless skin or muscle lump. It is diagnosed by lesion biopsy. In the involvement of the brain patient can present with neurological manifestation and it's known as neurocysticercosis which is the one of the most common cause of seizure especially in India. The diagnosis of cysticercosis can be by MRI, serological test, and complete blood count that can show eosinophilia [12]. One of the rarest manifestations of cysticercosis is tongue nodule or mass which occur only for 34 cases over the world. It's usually not detected by clinician; the diagnostic keystone is done by histopathology which represents the larva of the *TaeniaSolium* [13]. Also taenia spp. can lead to cysticercosis in which the larval stage of taenia involved the tissues or the central nervous system which can

lead to epilepsy, and it's the most common cause of epilepsy in Mexico and other developing countries [8]. Cysticercosis is a common manifestation caused by larval stage of *TaeniaSolium* infection. Cysticercosis can invade the Sub-cutaneous tissues, brain, muscles, heart, liver, lungs, and peritoneum, while the intraoral involvement is rare and if it have been involved it occur in the tongue, labial or buccal mucosa, the mouth floor and the cheek muscle. Intra-oral manifestation present as painless nodular swelling which is diagnosed by history, clinical examination, excision biopsy and histopathology [1]. The diseases is mostly asymptomatic but patient can present with abdominal symptoms such as mild abdominal discomfort, nausea, loss of appetite, weight loss, and diarrhoea, or constipation and pruritus ani, uncommonly it can lead to acute pancreatitis, cholecystitis and gall bladder perforation. Infection of *TaeniaSaginata* can be more aggressive than *TaeniaSolium* infection. It can be due to larger and longer size of *TaeniaSaginata* [2]. Cysticercosis is common manifestation caused by *TaeniaSolium* infection. It developed into cysticerci that invade the muscle and the brain which is the most common site for cysts (60-90%) that can lead to neurocysticercosis, associated with high morbidity rate along with eye cyst which is less common than the brain cyst [7]. The disease is confirmed by the presence of the proglottids or eggs in the faeces. The available treatment is Praziquantel, niclosamide, albendazole and nitazoxanide [2]. A 45 years old male came complaining of a painless solitary nodular swelling of his tongue for 2 months. Fine needle aspiration cytology was negative while excision biopsy and histopathology show cysticercosiscellulosae and the parasite showed along the tongue muscles [13]. A 23 years old new mother from Ethiopia who had a limited prenatal care that passed *Taenia strobili* after delivery, she was asymptomatic, and had been treated by praziquantel [8]. A chronic case of *TaeniaSaginata* which is resistant to niclosamide and albendazole but respond to a single dosage of praziquantel 15 mg per Kg body weight is reported. [2]Over 20 years 118 cases of orbital cyst had been surgically excised and by retrospective analysis it show sub-conjunctival 63%, intraocular 26%, orbital 7% and lid 4%. Three years old male child who diagnosed with orbital cysticercosis is reported [7]. A youngest case infected with *Taeniasaginata is reported in Thailand with no family history of disease* [14]

2. Case Report

An old female patient of 64 years of age was admitted to our Outpatient Clinic at Elhassaheisa Teaching Hospital, Gezira State, Sudan; December 2019 – complaining of penetrating abdominal trauma of 30 minutes duration. On examination patient looks unwell, not pale, vitally stable (PR: 90 B. M, RR: 18, BP: 120/70 mm/Hg), fully conscious, abdomen moving with respiration with an open wound at the umbilical region with minimal amount of bleeding through the same site, there is a localized swelling occupying the umbilical and the right lumbar regions, and there is a tape worm moving outside the abdomen through the site of trauma which is of about 97cm

long (Figure 1). Two large intravenous canulae was inserted and patient received 1 liter of Normal Saline, anti tetanus shot as well as I. V. antibiotics.

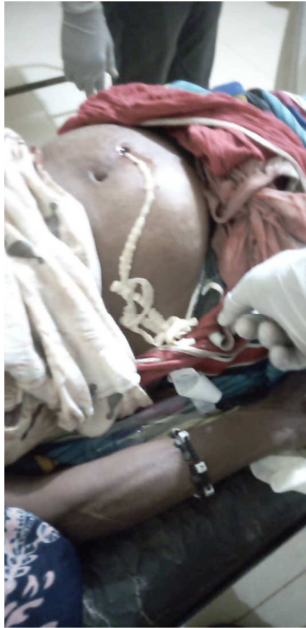

Figure 1. Tape-worm emerging from the site of penetrating abdominal wound in a case presented with penetrating abdominal trauma at the Outpatient Clinic, Elhassaheisa Teaching Hospital, Gezira State, Sudan; December 2019.

Laboratory findings were as follow: Hb: 9.1 g/l, leukocytes: $9.1 \times 10^3/\mu\text{l}$, with deferential; neutrophil: 96%, lymphocyte: 22%, Monocytes: 5%, Eosinophil: 3%, platelets: $7 \times 10^9/\text{l}$. viral screening for HIV, HBV, and HCV was negative. Patient was observed closely for monitoring PR, RR, and BP. Her state was deteriorated; so an emergency laparotomy was done with suspicion of perforate viscous. Operative finding showed that ileum was eviscerated through the lineasemilunaris with perforation at three sites about 60cm from the ileacecal valve (Figure 2 & Figure 3)

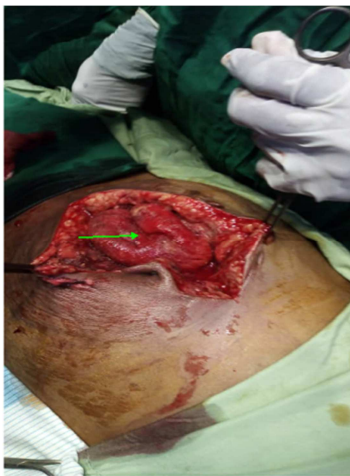

Figure 2. Herniation of the small bowel through the lineasemilunaris (marked by arrow) in a case of Teianiasis presented with penetrating abdominal trauma (marked by arrow) at the Outpatient Clinic, Elhassaheisa Teaching Hospital, Gezira State, Sudan; December 2019.

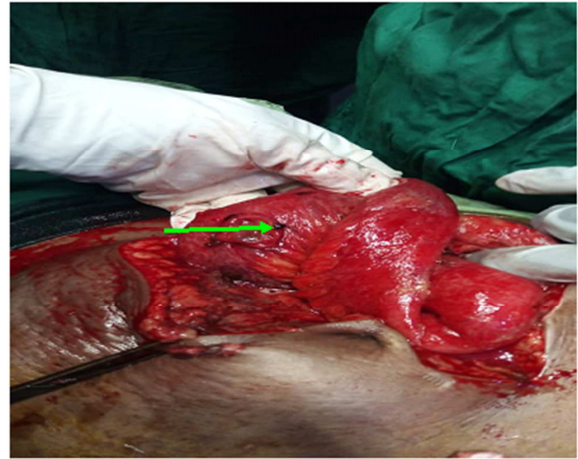


Figure 3. One of the sites of perforation of the small intestine in a case of Teianiasis presented with penetrating abdominal trauma (marked by arrow) at the Outpatient Clinic, Elhassaheisa Teaching Hospital, Gezira State, Sudan; December 2019.

Primary resection and anastamosis was done for the affected part involving 43cm of the ileum sutured by double layer using vicryl 2.0, the defect of the lineasemilunaris was approximated by vicryl 1, pelvic drain was fixed, hemostatis was secure, reconstruction of anatomy was done, no intra-operative complications, and no other tape-worm was observed. Patient had a history of eating raw meats as traditional food in our country, a history of loss of appetite, cholecystitis and frequent epigastric pain. Screening for T. Saginata was positive for the patient and negative for her family. Patient was defasted on day three of operation and was discharged on day 7 of operation in a good condition without complications and on Albendazole tab. Seven days after discharge she came for follow up and she was quite well. The histopathology of the resected part showed intact mucosa, serosal ulceration with dense infiltration of neutrophils and no evidence of granuloma or neoplasia.

3. Discussion and Conclusion

Intestinal perforation size in this case was of adequate size through which tape-worm can emerge out of intestine. So, most probably this was the situation; i.e. worm emerged through perforation of intestine then through umbilical wound to exterior. This patient had a history of symptoms regarding teianiasis like loss of appetite, cholecystitis and frequent epigastric pain together with a history of eating raw meat. So, it is a typical case of teianiasis. Regarding history of eating uncooked meat, this is consistent with what was reported by others [2, 3, 8, 12]. For type of taenia i.e. teianiasaginata, patient is Muslim, so, she did not used to eat pig meat which is associated with teianiasolium. This is similar to what was mentioned globally [3]. Symptoms that found in this case and favoring diagnosis of taeniasis like loss of appetite, cholecystitis and frequent epigastric pain are also reported internationally [2, 8, 12]. About family history our case is similar to other findings [14].

References

- [1] Riju J. J. AM S. K. and Sashikala P. Cysticercosis of Cheek: A Case Report, *J Microbiol Pathol*, 2018; Volume 2 Issue 2.
- [2] Mohanty A, Singh T. S., Bhutia T. O, Gupta P, Gupta P. A case of albendazole and niclosamide resistant *Taeniasaginata* infection, *International Journal of Research in Medical Sciences* | June 2017 |Vol 5| Issue 6 pp 2821-2823.
- [3] Ahsan S, Zia S. A, Ahmed J. Case Report A Case of *TineaSaginata* (tape worm) Infestation of the uterus presenting with abnormal vaginal bleeding, *J Pak Med Assoc*, August 2006, Vol. 56, No. 8, pp 377-378.
- [4] Dural A. C, et al. *Case Report* Unusual clinical case: Extra-luminal manifestation of a tapeworm from the eviscerated midline incision in a post-surgery patient, *J Infect Dev Ctries* 2015; 9 (4): 428-430.
- [5] Kumar S, Kumar S, Kumar M, Gautam S, Shidhartha K. Ileal perforation and peritonitis due to taenia a rare case. *International Journal of Scientific and Research Publications*, December 2014, Volume 4, Issue 12.
- [6] Meena R, Mittal A, Samar N, Prajapati M. Albendazole Resistant Neurocysticercosis- Rare Unusual Case Report. *Int J Cur Res Rev*, February 2018| Vol 10 Issue 3, pp 7-9.
- [7] Tiwari A. K, Gupta S, and Kumar M. Orbital Cysticercosis- A Case Report of Youngest Child Infected with *TaeniaSolium*, *JIMSA* April - June 2010 Vol. 23 No. 2, pp 93.
- [8] Noss M. R, Gilmore K, Wittich A. C. A Case of Taeniasis Diagnosed Postpartum, *MILITARY MEDICINE*, April 2013, Vol. 178, pp 516-519.
- [9] Najih M., et al. Case report *Taeniasaginata*: an unusual cause of post-appendectomy faecal fistula. *Pan African Medical Journal*. 2016; 25: 200 doi: 10.11604/pamj.2016.25.200.11003.
- [10] Ish S, Pathak A, Sharma R, and Hasan S. An Interesting Case of Subconjunctival Cysticercus Cyst: A Case Report, *J Eye Dis Disord*, Vol. 4 Iss. 2 No: 1000130.
- [11] Gupta C and Alam M. S. A case of non-resolving subconjunctivalcysticercosis managed by surgical excision, *Sci J Med & Vis Res Foun* October 2016|volume XXXIV| number 3|pp 67-69.
- [12] Singh A. P, Maurya D. P, Gupta P, Tanger R, Goyal R. B, and Sharma M. A Rare Case of Cysticercosis of the Abdominal Wall, *International Journal of Scientific Study* |September 2014|Vol 2| Issue 6, pp149-150.
- [13] Pandey S. C, and Pandey S. D. Case Report: Lingual cysticercosis, *Indian J PlastSurg* July-December 2005 Vol 38 Issue 2, pp 160-161.
- [14] Sitcharungsi R and Watthanakulpanich D. Case report; *Taeniasaginata* infection in a 14-month-old toddler, *Southeast Asian J Trop Med Public Health*, May 2016; Vol 47 No. 3 pp: 394-398.